

## Breast Deformity in Adolescence as a Result of Pneumothorax Drainage During Neonatal Intensive Care

Christian Rainer, MD\*; Alexander Gardetto, MD\*; Martin Frühwirth, MD‡; Rudolf Trawöger, MD‡; Romed Meirer, MD\*; Helga Fritsch, MD§; and Hildegunde Piza-Katzer, MD\*

**ABSTRACT.** *Objective.* During intensive care of newborns, a number of invasive techniques may be necessary for resuscitation. The margin of safety between effective treatment and iatrogenic damage is narrow. The objective of this study was to identify and discuss iatrogenic damage in females resulting from treatment of pneumothorax and to give neonatologists anatomically based advice for prevention.

*Patients and Methods.* We report 2 female patients (aged 13 and 16 years) born prematurely in whom breast deformity occurred caused by drainage of multiple pneumothoraces during intensive care. In an additional anatomic study, both hemithoraces of 5 newborn female cadavers ( $n = 10$ ) were dissected to measure the extension of the breast tissue.

*Results.* The anatomic investigations in newborns demonstrate that breast tissue extends vertically from the second or third rib to the sixth rib and from close to the sternal edge medially, almost to the anterior axillary line laterally.

*Conclusion.* Psychological distress and corrective surgery because of deformed breasts in adolescent girls who have undergone drainage of pneumothoraces as newborns can be avoided by placing the skin incision in the anterior axillary line, maintaining a distance of 4 to 5 cm inferior to the nipple, and by inserting the chest drain through the fifth or sixth intercostal space during neonatal treatment. *Pediatrics* 2003;111:80–86; *pneumothorax, chest drain, breast deformity, iatrogenic damage.*

Most newborn infants admitted to an intensive care unit are born prematurely, have major congenital abnormalities, or have suffered from birth complications. The majority will survive after a variable spell of intensive care. A number of invasive techniques may be necessary for resuscitation, but the margin of safety between effective treatment and iatrogenic damage is narrow. Serious iatrogenic complications of neonatal intensive care are uncommon but well described in literature.<sup>1</sup> They relate particularly to arterial catheterization,<sup>2,3</sup> extravasation of intravenous fluid into the tissues,<sup>4</sup> and insertion of chest drains.<sup>5</sup> However, many inva-

sive procedures involve the skin and scarring is common, which may have functional or aesthetic implications for the surviving child, particularly in females.<sup>6</sup> Scarring occurs if the basal layer of the epidermis, which generates the epidermal barrier, is lost or damaged. The very immature infant with a poorly developed barrier layer is particularly at risk, and iatrogenic damage is both more serious and more frequent<sup>7</sup> because these infants require a longer period of intensive care and are therefore often exposed to more invasive procedures.<sup>8</sup> In particular, scars from chest drains for treatment of pneumothoraces remain visible, and if the drains were placed in the mid-clavicular line, deformation of developing breasts may occur, which will become an embarrassment to the girls when they reach adolescence and adult life.

We report 2 young female patients who underwent the placement of multiple chest drains as newborns because of pneumothoraces. During adolescence they both developed bilateral breast deformities that made corrective surgery necessary. In an anatomic study on 5 female newborn cadavers, we measured the extension of the breast tissue and based our recommendations to avoid scarring and breast deformities on these data.

### PATIENTS AND METHODS

#### Case Reports

##### Case 1

A 16-year-old girl was referred to our department for aesthetic correction of both breasts. The left breast showed a deep scarred retraction at the lower-outer quadrant and a large scar 1 cm below the inframammary fold (Fig 1). On the right side, one scar was visible laterally in the inframammary fold and a second scar was visible in the anterior axillary line. The girl's medical records revealed that she was born prematurely because of edema-proteinuria-hypertension gestosis of the mother with a gestational age of 31 weeks and a birth weight of 1500 g. The infant developed a hyaline membrane syndrome and was therefore intubated and ventilated over 7 weeks. During this period, multiple pneumothoraces occurred, which made the insertion of chest drains (4 on the left and 2 on the right side) necessary. Because of the localization of the scars on the left side, the chest drains were placed near the mid-clavicular line, damaging the assembled breast tissue.

The developing deformities caused embarrassment and teasing, which became increasingly important when the girl reached adolescence. Therefore, corrective surgery on both breasts was done with adhesiolysis on the left breast and cicatrctomy on both sides. Adhesiolysis included excision and extripation of scar tissue reaching from the skin to the pectoral fascia. Normal adjacent glandular and fat tissue was mobilized from the pectoral fascia and readapted to avoid recurrence of a scarred retraction. The operation and the postoperative course were uncomplicated. One

From the \*Department of Plastic and Reconstructive Surgery, University of Innsbruck and Ludwig-Boltzmann Institute for Quality Control in Plastic Surgery, Innsbruck, Austria; and ‡Department of Pediatrics and §Institute of Anatomy and Histology, University of Innsbruck, Innsbruck, Austria. Received for publication Jan 28, 2002; accepted Jun 11, 2002.

Address correspondence to Christian Rainer, MD, Department of Plastic and Reconstructive Surgery, University of Innsbruck, Anichstrasse 35, A-6020 Innsbruck, Austria. E-mail: christian.rainer@chello.at  
PEDIATRICS (ISSN 0031 4005). Copyright © 2003 by the American Academy of Pediatrics.

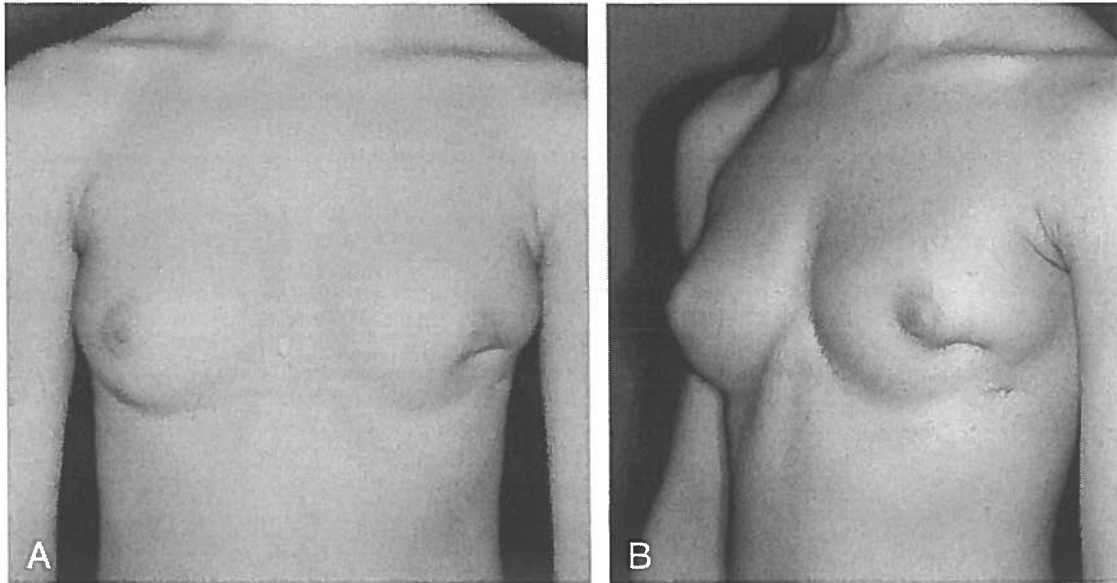


Fig 1. Sixteen-year-old female with a deep scarred retraction at the lower-outer quadrant and a large scar 1 cm below the inframammary fold on her left breast after placement of chest drains because of multiple pneumothoraces as preterm infant.

year postoperatively, the left breast showed a nearly normal shape and projection and scarring became acceptable (Fig 2A and B).

#### Case 2

This girl was born at 27 weeks' gestational age and ventilated over 6 weeks because of respiratory distress. During ventilation, pneumothoraces on both sides occurred and were treated by insertion of drains. Reoccurrence of pneumothorax made a reinsertion of a chest drain on both sides necessary. At the age of 13 years, the girl presented with distinct deformations on both breasts. On the left side, a deep scarred retraction at the lower-outer quadrant deformed the breast. On the right side, a  $3.5 \times 0.5$  cm adherent scar at the lower-inner quadrant and an additional 1-cm long adherent scar medially 1 cm below the inframammary fold led to a severe deformation of the breast (Fig 3). This situation was aggravated by a painful sensation of tension in both breasts. Corrective surgery on both breasts was performed with adhesi-

olysis and cicatrctomy. The postoperative course was uncomplicated. One year after surgery, the patient was free of pain in both breasts and showed normal breast development and glandular and adipose tissue spread (Fig 4).

#### Anatomic Study

In 5 female, newborn, formalin-fixed cadavers (mean gestational age: 38.4 weeks, range: 37–40 weeks, mean birth weight: 3.3 kg, range: 2.8–3.9 kg) both hemithoraces ( $n = 10$ ) were dissected to measure the extension of the breast tissue. The skin incision was conducted cranially along the clavicle, medially parasternal, and caudally along the costal arch until the posterior axillary line. After circumcision of the areola, the skin was mobilized, folded laterally, and the subcutaneous tissue was removed. The breast tissue and its borders were dissected carefully and its extension measured.

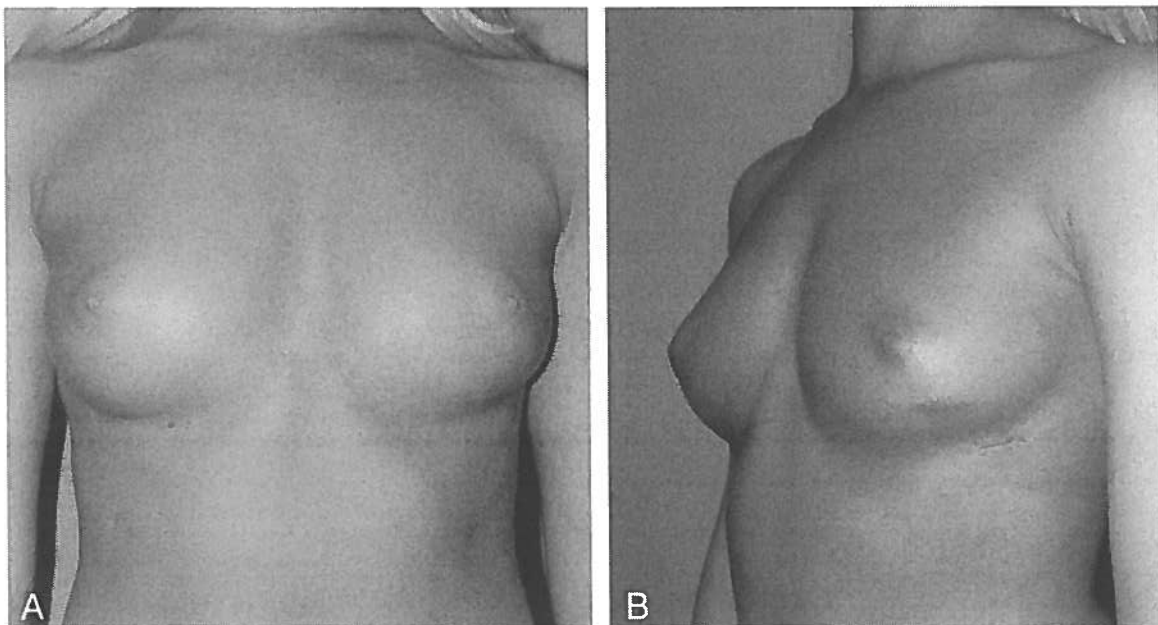


Fig 2. Result 1 year after corrective surgery with adhesiolysis and cicatrctomy.

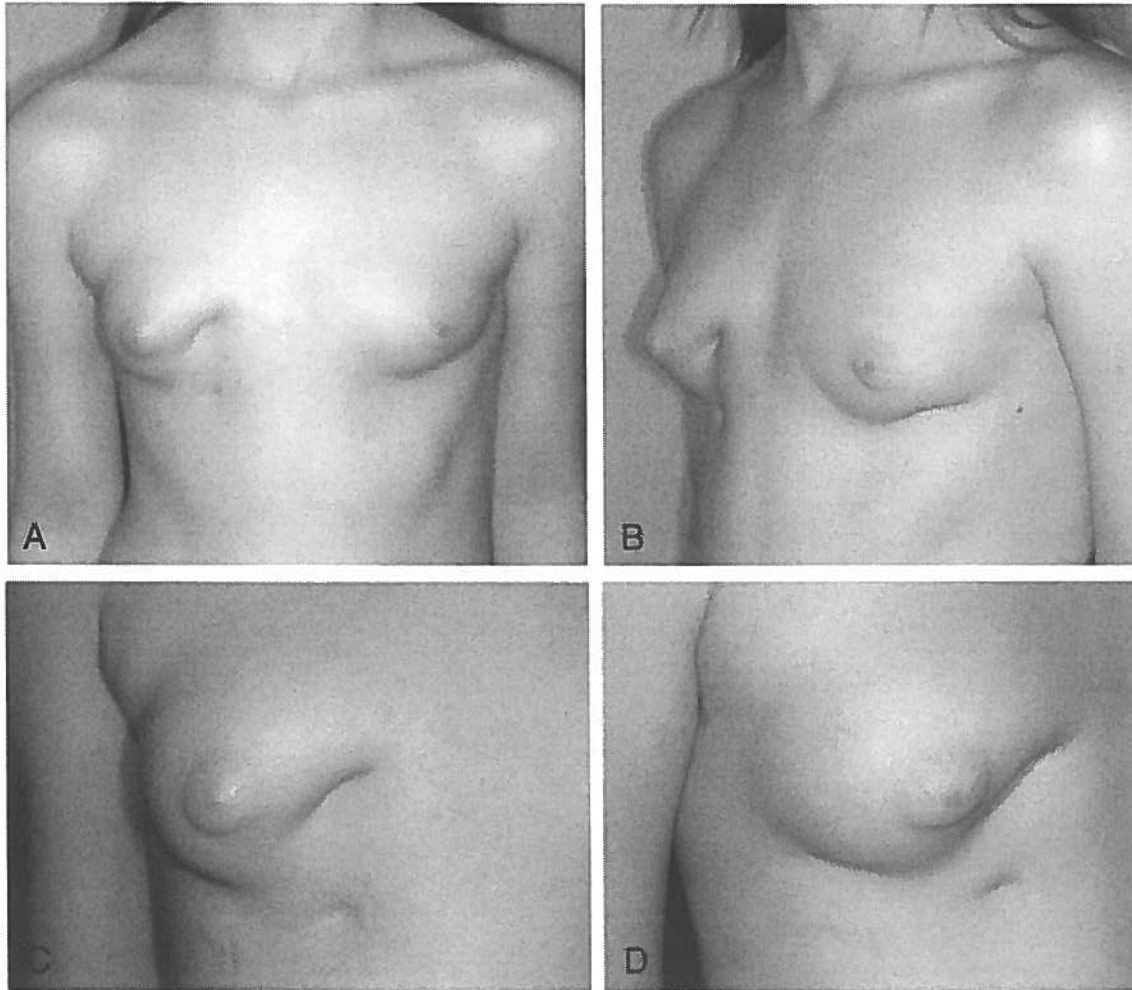


Fig 3. A and B, Thirteen-year-old girl with bilateral breast deformity after multiple pneumothoraces and treatment with chest drains. C and D, Closer view of the right breast. Note the adherent scar at the lower-inner quadrant and the adherent scar medially.

## RESULTS

### Anatomic Study

After removal of the skin and the subcutaneous tissue, a thin layer of fat and glandular breast tissue lying on the pectoralis major muscle could be identified (Fig 5). It extended vertically from the cranial border of the second or third rib to the caudal border of the sixth rib, and in the transverse plane from a distance of 2.21 cm (range: 1.9–2.5 cm) to the sternal edge to a distance of 0.43 cm (range: 0.3–0.6 cm) medial of the anterior axillary line. Mean vertical diameter (vertical line through the mamilla) of breast tissue was 10.13 cm (range: 9.9–10.4 cm), and the mean horizontal diameter (horizontal line through the mamilla) was 8.42 cm (range: 8.0–8.8 cm) (Table 1). The superolateral quadrant was prolonged toward the axilla along the inferolateral edge of pectoral major muscle.

### DISCUSSION

Pneumothorax, pneumomediastinum, pneumopericardium, and pneumoperitoneum are major complications of respiratory diseases, continuous positive airway pressure, mechanical ventilation

with or without positive end-expiratory pressure, cardiopulmonary resuscitation, and catheterization of central veins.<sup>9</sup> Mechanical ventilation, often necessary in preterm infants, was a frequent cause of pneumothorax in earlier years. Because of the use of antenatal steroids and surfactant, mechanical ventilation and the incidence of air leaks in preterms have significantly decreased. However, in preterm and newborn infants intrathoracic extrapulmonary collection of air remains potentially life-threatening by causing compression of vital structures. Thus, insertion of chest drains for lung-decompression is mandatory, especially when a patient receives artificial respiration and the pneumothorax is attributed to mechanical ventilation.<sup>9</sup> However, individual neonatologists might be less experienced so malplacement of chest tubes still can occur. It is well known that scarring relating to chest drain insertion and fixation remains significant.<sup>1,6</sup> However, different recommendations for the correct placement of chest drains can be found in literature. Currently, 2 major sites of insertion—an anterior (mid-clavicular line) and a lateral (anterior axillary line)—are recommended, and the anterior site is sometimes preferred because the

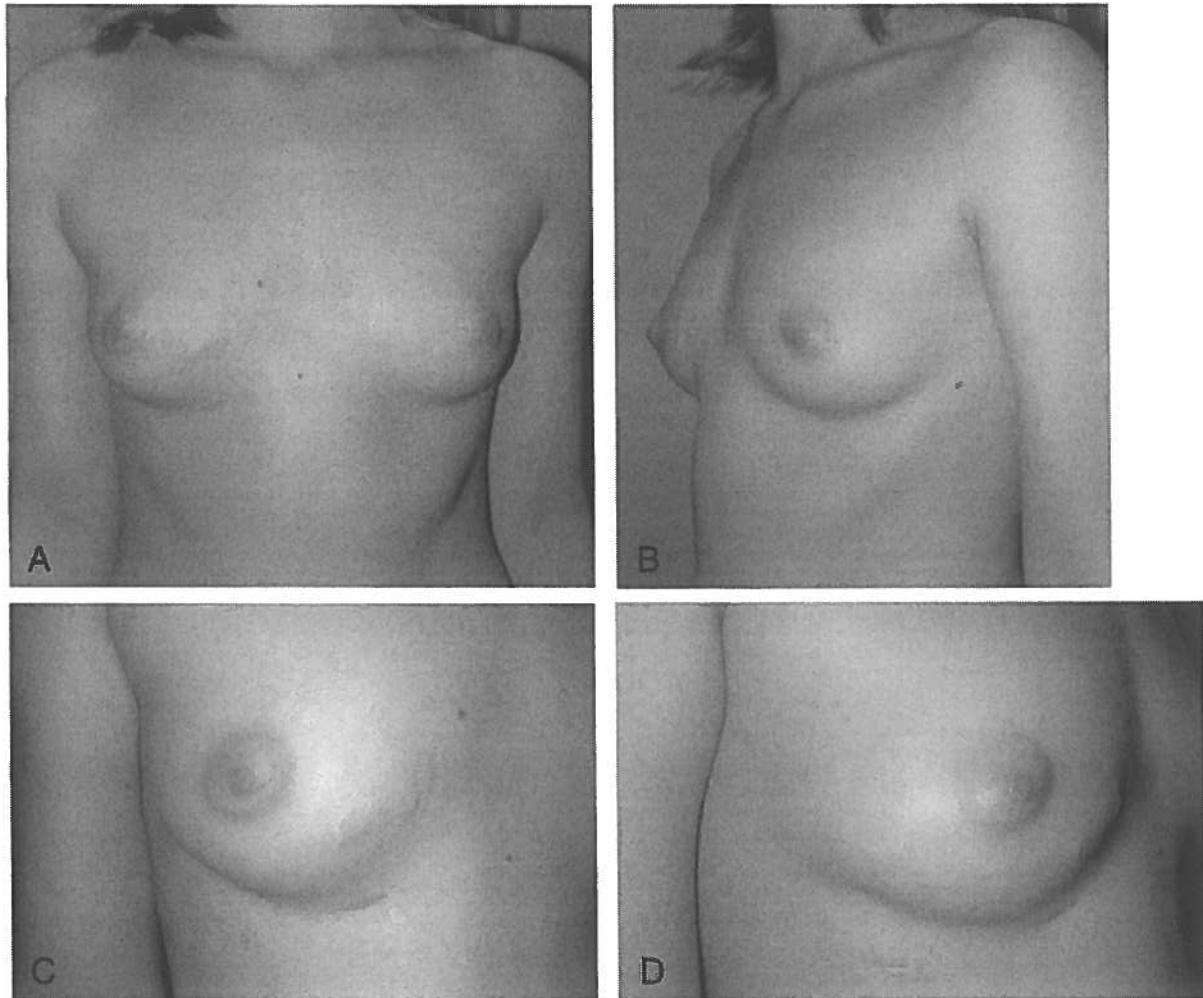


Fig 4. Postoperative view 1 year after adhesiolysis and cicatrixectomy.



Fig 5. Extension of the breast tissue in a female newborn cadaver. Note caudal extension to the lower border of the sixth rib.

drain tip is more likely to end up in front of the lung where the air collects. Pfenninger et al<sup>9</sup> recommend a skin incision 3 cm below the nipple in mid-clavicular line. Fletcher and Eichelberger<sup>10</sup> also consider the mid-clavicular line at fourth to fifth intercostal space

just over top of fifth or sixth rib as the correct point for drain insertion in emergency evacuation of air leaks to stay below the breast tissue. In contrast to the emergency procedure, the same authors recommend the sixth or seventh intercostal space for skin incision and the fourth or fifth intercostal space between mid-axillary and anterior axillary line for pleura entry for permanent tube placement. Nevertheless, Hougaard and Arendrup<sup>11</sup> stated that a distance of at least 3 to 5 cm from the nipple, depending on the age of the girl, in all operative procedures on the thorax, including the insertion of a pulmonary drain, should be maintained to avoid damage to the breasts. Genc et al<sup>12</sup> recommend the sixth intercostal space at the mid-axillary line for thoracostomy procedures, because a wound scar in mid-axillary line has a more aesthetic appearance when compared with the scar in the mid-clavicular line.

We share the opinion of Hougaard and Arendrup who state that the development of breast deformity and of scar tissue results from underestimation of the extent of mammary tissue in children.<sup>11</sup> In adult females, the base of the breast (its attached surface) extends vertically from the second to the sixth rib and in the transverse plane, from close to the sternal

TABLE 1. Extension of Breast Tissue in 5 Female Newborn Cadavers

Newborn Cadaver (n = 5)	Site	Diameter (cm)		Cranial Border (Rib)	Caudal Border (Rib)	Medial Border* (cm)	Lateral Bordert (cm)
		Vertical	Horizontal				
1	Right	10.0	8.5	II	VI	2.5	0.5
	Left	10.0	8.6	II	VI	2.4	0.4
2	Right	9.9	8.0	III	VI	2.1	0.3
	Left	10.1	8.1	II	VI	1.9	0.4
3	Right	10.3	8.1	II	VI	1.9	0.3
	Left	10.4	8.1	II	VI	2.1	0.4
4	Right	10.2	8.8	III	VI	2.2	0.5
	Left	10.3	8.7	III	VI	2.3	0.3
5	Right	10.1	8.6	II	VI	2.4	0.6
	Left	10.0	8.7	II	VI	2.3	0.6

\* Distance to the sternal edge.

† Distance to the anterior axillary line.

edge, medially, almost to the anterior axillary line, with a wedge of glandular tissue radiating to the axilla.<sup>13,14</sup> The general opinion seems to be that the extent of such tissue is somewhat less in children, but this is incorrect.<sup>11</sup> In prepubertal girls, the anlage of glandular tissue has been demonstrated to have the same topographical distribution as in adult females.<sup>11,15</sup> In our anatomic study a similar extension of premature breast tissue in newborns could be demonstrated (Fig 5), and we assume no great variations in preterms. In all of our specimens, the breast tissue extended to the lower border of the sixth rib. Placement of the chest drain in the mid-clavicular line just over top of fifth or sixth rib, as recommended by Fletcher and Eichelberger,<sup>10</sup> would not be below the breast tissue and thus may lead to breast deformity.

During externally recognizable breast development from puberty onward, there is no significant increase of the extension of the base of the breast (its attached surface). Breast development mainly takes place as proliferation of glandular, connective, and adipose tissue projecting the breast from the chest wall as a single mass within the prenatally determined extension of the base of the breast.<sup>14</sup> However, with increasing age and in very adipose patients, the inframammary fold can decline to the level of the seventh rib and the lateral border can extend beyond the anterior axillary line.<sup>16</sup> The site of breast tissue, however, also is partially dependent on the shape of the thorax so it is possible that the localization is more medial in girls with funnel chest than in those with normal chest configurations.<sup>11,15</sup>

During newborn and infant age, only a thin layer of fat and premature glandular tissue exists, and a scar placed in this region may lead to adhesion of the dermal layer of the skin to the deep pectoral fascia. Before breast growth only the scar itself becomes apparent, but this dermal adhesion usually remains without recognition or symptoms. As soon as the girl enters puberty and breast tissue undergoes proliferation of glandular and fatty tissue mediated by estrogen and progesterone,<sup>17</sup> this adhesion becomes obvious by fixing the skin to the pectoral fascia and inhibiting proportionate expansion. Painful sensation of tension and underdevelopment of breast tissue with severe deformity formation and, in some of

the most severe cases, the inability to breast feed, may result. In addition, one must not forget that a female patient who has a deformed breast experiences considerable psychological distress. To avoid these complications, corrective surgery in terms of cicatrixectomy and adhesiolysis should be performed as soon as breast development begins. If such surgery is undertaken too invasive and before the beginning of breast development, already assembled premature glandular tissue could be harmed and full breast development may be impaired as well. Furthermore, the full extent of adhesion will only be visible when the breast already started to grow. However, if the breasts have developed and a non-corrected scar formation with subsequent breast deformity that lead to a fixed hypoplasia of 1 or both breasts has occurred, corrective surgical procedures will have to be more invasive and the patient is at higher risk, as breast reconstruction techniques using autologous pedicled or free microvascular tissue transfer or insertion of breast implants will have to be performed.<sup>18</sup>

It is understandable that in a potentially life-threatening pneumothorax in a preterm, the treating neonatologist may consider the effect on breast development when placing the chest drain as secondary. However, damage to the breast could be avoided by keeping outside of the assembled breast tissue. Based on the recommendations in literature and supported by our anatomic study, we suggest the following procedure for insertion of the chest drain at the lateral site: after analgosedation a linear skin incision along the relaxed skin tension lines that run parallel to the underlying ribs should be made 4 to 5 cm below the nipple just posterior to the anterior axillary line (Fig 6A). A subcutaneous track should be created by blunt dissection with a curved hemostat, and a hole should be tunneled through the fifth intercostal space, immediately above the upper border of the lower rib, again by blunt technique with the curved hemostat (Fig 6, B and C). The chest drain should then be grasped by the hemostat and introduced through the formerly created tunnel into the air pocket. After insertion the drain should be fixed carefully with adhesive tape to avoid blisters. We do not recommend purse-string sutures, as they may result in puckering of the skin.<sup>1</sup> After removal of the

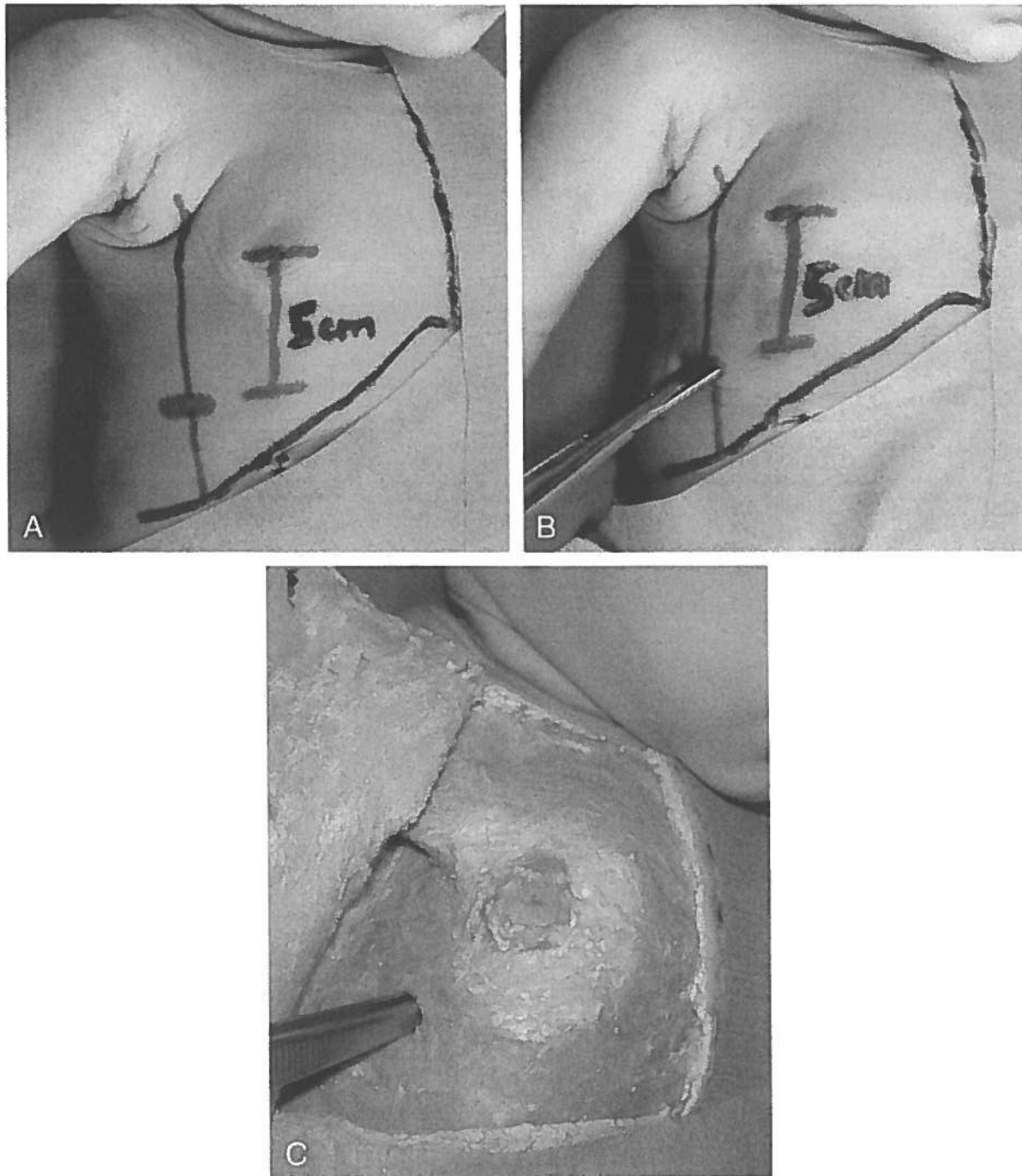


Fig 6. A, Marked anterior axillary line and planned incision 5 cm below the mamilla. B and C, Insertion of the hemostat through the fifth intercostal space. Note that insertion is performed well outside the assembled breast tissue.

drain, the linear incision should be held together by thin adhesive strips or thin (ie, 6.0) sutures. If a reinsertion of a chest drain is necessary, the former incision could be used or a new incision lateral to the former—between anterior axillary and mid-axillary line—should be performed.

If the anterior site is chosen for insertion, the chest tube must strictly be inserted in the second intercostal space in the mid-clavicular line. This would avoid breast tissue damage in most cases, but does, however, result in a more visible scar.

#### CONCLUSION

We recommend insertion of chest drains in pre-term and newborn infants in the anterior axillary line through the fifth intercostal space after a skin incision 4 to 5 cm below the mamilla to avoid developmental disorders and restriction of breast growth.

#### ACKNOWLEDGMENT

We thank Lynn Rhoades for her editorial review of the manuscript.

## REFERENCES

1. Fox PE, Rutter N. The childhood scars of newborn intensive care. *Early Hum Dev.* 1998;51:171-177
2. Cartwright GW, Schreiner RL. Major complication secondary to percutaneous radial artery catheterization. *Pediatrics.* 1980;65:139-141
3. Simmons MA, Levine RL, Lubchenko LO, Guggenheim MA. Warning: serious sequelae of temporal artery catheterization. *J Pediatr.* 1978;92:284
4. Davies J, Gault D, Buchdahl R. Preventing the scars of neonatal intensive care. *Arch Dis Child.* 1994;70:50-51
5. Maessinger AC, Driscoll JM, Wigger HJ. High incidence of lung perforation by chest tube in neonatal pneumothorax. *J Pediatr.* 1978;92:635-637
6. Carlidge PH, Fox PE, Rutter N. The scars of newborn intensive care. *Early Hum Dev.* 1990;21:1-10
7. Keeling JW, Bryan EM. Iatrogenic disease. In: Harvey D, Cooke RWI, Levitt GA, eds. *The Baby Under 1000 g.* London, United Kingdom: Wright; 1989:289-303
8. Barker DP, Rutter N. Exposure to invasive procedure in neonatal intensive care. *Arch Dis Child.* 1995;72:203-204
9. Pfenninger J, Bossi E, Biesold J, Blumberg A. Treatment of pneumothorax, pneumopericardium and pneumomediastinum. *Helv Paediatr Acta.* 1982;37:353-360
10. Fletcher MA, Eichelberger MR. Thoracostomy tubes. In: Fletcher MA, Mac Donald MG, eds. *Atlas of Procedures in Neonatology.* Philadelphia, PA: Lippincott; 1993:309-329
11. Hougaard K, Arendrup H. Deformities of the female breast after surgery for funnel chest. *Scand J Thor Cardiovasc Surg.* 1993;17:171-174
12. Genc A, Özcan C, Erdener A, Mutaf O. Management of pneumothorax in children. *J Cardiovasc Surg.* 1998;39:849-851
13. Converse JM, ed. *Reconstructive Plastic Surgery.* 2nd ed. Philadelphia, PA: Saunders; 1977:3633
14. Collins P. Female breast. In: Williams PL, Bannister LH, Berry MM, et al, eds. *Gray's Anatomy.* New York, NY: Churchill Livingstone; 1995:418-424
15. Martin R, ed. *Lehrbuch der Anthropologie [Textbook of Anthropology].* Stuttgart, Germany: Gustav Fischer Verlag; 1979:890
16. Bohmert H, ed. *Plastische und rekonstruktive Chirurgie der Brust [Plastic and Reconstructive Surgery of the Breast].* New York, NY: Thieme; 1995:3
17. Langman J, ed. *Medizinische Embryologie [Embryology].* 7th ed. New York, NY: Thieme; 1985:380
18. MacLennan SE, Wells MD, Neale HW. Reconstruction of the burned breast. *Clin Plast Surg.* 2000;27:113-119

## THE TOILET WARS IN JAPAN

"Nara, Japan—Japan's toilet wars started in February, when Matsushita engineers. . . unveiled a toilet seat equipped with electrodes that send a mild electric charge through the user's buttocks, yielding a digital measurement of body-fat ratio. . . Unimpressed, engineers from a rival company, Inax, counterattacked in April with a toilet that glows in the dark and whirs up its lid after an infrared sensor detects a human being. When in use, the toilet plays any of 6 soundtracks, including chirping birds, rushing water, tinkling wind chimes, or the strumming of a traditional Japanese harp. . . Matsushita introduced in May a \$3000 throne that not only greets a user by flipping its lid, but also by blasting its twin air nozzles—air-conditioning in the summer, heat in the winter. . . Then, in June, Toto, Japan's toilet giant, came out with WellyouII, a toilet that automatically measures the user's urine sugar levels by making a collection with a little spoon held by a retractable, mechanical arm. . . Talking toilets are on the horizon. Equipped with microchips, these models would go beyond music, greeting each user with a personalized message. . . the real growth will be medical toilets linked to the Internet. 'You may think a toilet is just a toilet, but we would like to make a toilet a home health measuring center.' Mr. Matsui, the Matsushita engineer, said in a lecture [here] in Nara, near Osaka. 'We are going to install in a toilet devices to measure weight, fat, blood pressure, heart beat, urine sugar, albumin, and blood in the urine.' The results would be sent from the toilet to a doctor by an Internet-capable cellular phone built into the toilet."

Brooke J. *New York Times.* October 8, 2002

Noted by JFL, MD

**Breast Deformity in Adolescence as a Result of Pneumothorax Drainage During Neonatal Intensive Care**

Christian Rainer, Alexander Gardetto, Martin Frühwirth, Rudolf Trawöger, Romed Meirer, Helga Fritsch and Hildegunde Piza-Katzer

*Pediatrics* 2003;111;80-86

DOI: 10.1542/peds.111.1.80

<b>Updated Information &amp; Services</b>	including high-resolution figures, can be found at: <a href="http://www.pediatrics.org/cgi/content/full/111/1/80">http://www.pediatrics.org/cgi/content/full/111/1/80</a>
<b>References</b>	This article cites 10 articles, 1 of which you can access for free at: <a href="http://www.pediatrics.org/cgi/content/full/111/1/80#BIBL">http://www.pediatrics.org/cgi/content/full/111/1/80#BIBL</a>
<b>Subspecialty Collections</b>	This article, along with others on similar topics, appears in the following collection(s): <b>Premature &amp; Newborn</b> <a href="http://www.pediatrics.org/cgi/collection/premature_and_newborn">http://www.pediatrics.org/cgi/collection/premature_and_newborn</a>
<b>Permissions &amp; Licensing</b>	Information about reproducing this article in parts (figures, tables) or in its entirety can be found online at: <a href="http://www.pediatrics.org/misc/Permissions.shtml">http://www.pediatrics.org/misc/Permissions.shtml</a>
<b>Reprints</b>	Information about ordering reprints can be found online: <a href="http://www.pediatrics.org/misc/reprints.shtml">http://www.pediatrics.org/misc/reprints.shtml</a>

American Academy of Pediatrics

DEDICATED TO THE HEALTH OF ALL CHILDREN™



# PEDIATRICS®

OFFICIAL JOURNAL OF THE AMERICAN ACADEMY OF PEDIATRICS

## **Breast Deformity in Adolescence as a Result of Pneumothorax Drainage During Neonatal Intensive Care**

Christian Rainer, Alexander Gardetto, Martin Frühwirth, Rudolf Trawöger, Romed Meirer, Helga Fritsch and Hildegunde Piza-Katzer

*Pediatrics* 2003;111:80-86

DOI: 10.1542/peds.111.1.80

The online version of this article, along with updated information and services, is located on the World Wide Web at:

<http://www.pediatrics.org/cgi/content/full/111/1/80>

PEDIATRICS is the official journal of the American Academy of Pediatrics. A monthly publication, it has been published continuously since 1948. PEDIATRICS is owned, published, and trademarked by the American Academy of Pediatrics, 141 Northwest Point Boulevard, Elk Grove Village, Illinois, 60007. Copyright © 2003 by the American Academy of Pediatrics. All rights reserved. Print ISSN: 0031-4005. Online ISSN: 1098-4275.

American Academy of Pediatrics

DEDICATED TO THE HEALTH OF ALL CHILDREN™

