

Case report

Shock wave therapy: An innovative treatment method for partial thickness burns

R. Meirer^{a,b,c,*}, F.S. Kamelger^{a,b,c}, H. Piza-Katzer^{a,b,c}

^a Department of Plastic and Reconstructive Surgery, Leopold-Franzens University, Anichstrasse 35, A-6020 Innsbruck, Austria

^b Medical University of Innsbruck, Austria

^c Ludwig-Boltzmann-Institute for Quality Control in Plastic and Reconstructive Surgery, Austria

1. Introduction

Deep partial thickness burns are characterized by the fact that they take over 21 days to heal and scarring may be severe. As differentiation from full thickness burns is often difficult the majority of cases are skin grafted with early excision beginning within less than 72 h as it is said to be beneficial especially in children and young adults less than 30 years old [1]. This report presents an innovative idea to treat deep partial thickness burns.

2. Case report

A 31-year-old man presented to our department, with deep partial thickness burns on his right forearm. This injury was sustained while cooking for his son using hot oil. As the burn was very painful the patient was transferred to the OR for general anesthesia to clean the burn with skin disinfectant. Consecutively, fine mesh gauze was applied as wound dressing. The dressing was changed once daily. Forty-eight hours after the accident the wound had a cheesy color and was waxy dry (Fig. 1). We recommended an excision of the burn area and skin grafting as a differentiation to a full thickness burn was not possible. The patient refused any skin grafting for cosmetic reasons. With the consent of the patient we used on the basis of our experimental data extracorporeal shock wave (ESW) therapy for burns treatment.

Shock waves are defined as sonic pulses. They consist of transient pressure fluctuations with three-dimensional spreading. Although ESW therapy has got a 30-year-old

history in lithotripsy [2], its use in orthopedic and traumatological applications is recent. In animal experiments conducted in our lab we found an impressive reduction of skin necrosis in flaps [3] using shock wave therapy compared to a control group and a significant rise of angiogenesis related growth factors (data not yet published). We concluded that if ESW therapy enables us to improve vascularisation in ischemic tissue it might be beneficial for burn injuries as the reepithelization might be progressed.

In concordance with the patient we treated the burn area at days 3 and 7 after the injury with ESW therapy. Ultrasound transmission gel was used as contact medium between the ESW apparatus and skin. Both ESW treatments consisted of 1500 impulses at 0.11 mJ/mm² each (Evotron, High Medical Technologies, Lengwil, Swiss).

At day 15 after the burns nearly the whole wound was reepithelized (Fig. 2). The 6-month follow-up revealed an uneventfully healed wound without scarring (Fig. 3).

3. Discussion

Recent results of animal studies suggest that ESW treatment stimulates the early expression of a wide array of growth factors endogenously. Wang stated that there is a significant rise of growth factors such as endothelial nitric oxide synthase, vascular endothelial growth factor and proliferating cell nuclear antigen inducing growth of new vessels [4]. In a subsequent study Wang et al. demonstrated that ESW treatment is effective in promoting the healing of fractures and injuries by stimulated expression of the growth factors [5] mentioned above as well as tumour growth factor-β1 [6]. Based on our experimental data, we wanted to investigate whether this approach was feasible and useful from the perspective of burns treatment.

* Corresponding author. Tel.: 43 512 504 2731; fax: 43 512 504 2735.
E-mail address: romed.meirer@uibk.ac.at (R. Meirer).

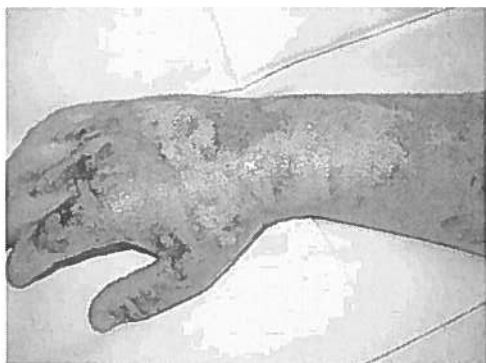


Fig. 1. Forty-eight hours after the accident the wound had a cheesy color. We recommended an excision of the burn area.

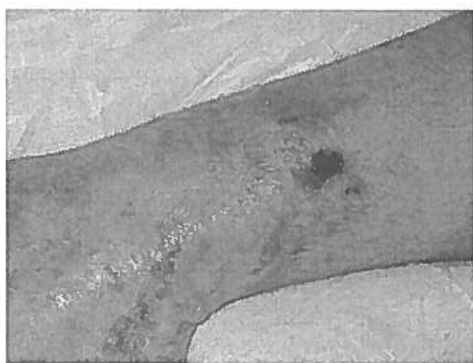

Fig. 2. At day 15 after the burns nearly the whole wound was reepithelialized.

It was postulated that ESW treatment may cause microtrauma and hematoma formation but according to available literature the incidence of shock wave complications varies significantly with the location of treatment and the amount of shock wave energy [7]. As the ESW treatment we applied consisted of 2 series of 1500 impulses at 0.11 mJ/mm^2 , which represents a low-dose treatment, we did not encounter any complications.

In clinical practice ESW treatment seems to be painful for the patient. It might be useful to apply this technique in general anesthesia which could be done in one setting when the patient has to be transferred to the OR to clean the burn with skin disinfectant. In an animal experiment we also found a significant faster wound healing in the ESW group compared to a control group (data not yet published). Although in this case treatment with shock wave therapy resulted in healing of the wound, a treatment which was also promising in animal models, this modality has not been tested in humans. In fact, there is a chance it could be detrimental. However, given the promising results so far, the

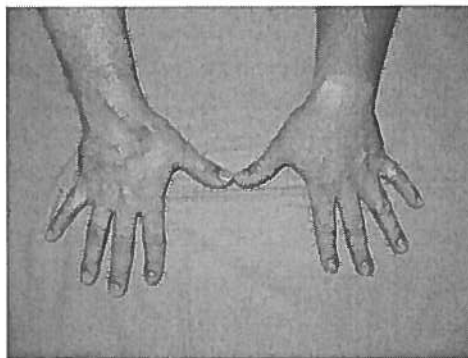


Fig. 3. Six months after the burn trauma the burned area was epithelialized and had been healed without any scarring.

effects of shock wave therapy on burn wound healing should be tested in a clinical trial.

4. Conclusion

Although further studies have to be conducted to prove these successful findings in several burns patients this technique might represent a feasible and cost effective method. Treatment of partial thickness burns with ESW therapy might make a surgical intervention unnecessary. Skin grafting could be prevented which would improve the aesthetic outcome and consecutive operations like scare contracture release could be prevented. ESW is already successfully used in the treatment of urologic and orthopaedic disorders; it may soon prove its value in burns.

References

- [1] Herndon DN, Barrow RE, Rutan RL, Rutan TC, Desai MH, Abston S. A comparison of conservative versus early excision. Therapies in severely burned patients. *Ann Surg* 1989;209:547–52.
- [2] Bihl G, Meyers A. Recurrent renal stone disease: advances in pathogenesis and clinical management. *Lancet* 2001;358:651–6.
- [3] Meirer R, Kamelger FS, Huemer GM, Wanner S, Piza-Katzer H. Extracorporeal shock wave may enhance skin flap survival in an animal model. *Br J Plast Surg* 2005;58:53–7.
- [4] Wang CJ. An overview of shock wave therapy in musculoskeletal disorders. *Chang Gung Med J* 2003;26:220–32.
- [5] Wang CJ, Wang FS, Yang KD, et al. Shock wave therapy induces neovascularization at the tendon–bone junction. A study in rabbits. *J Orthop Res* 2003;21:984–9.
- [6] Wang FS, Yang KD, Chen RF, Wang CJ, Sheen-Chen SM. Extracorporeal shock-wave promotes growth and differentiation of bone-marrow stromal cells towards osteoprogenitors associated with induction of TGF-beta1. *J Bone Joint Surg Br* 2002;84:457–61.
- [7] Wang CJ, Huang HY, Yang K, Wang FS, Wong M. Pathomechanism of shock wave injuries on femoral artery, vein and nerve. An experimental study in dogs. *Injury* 2002;33:439–46.