

# Pollicization of the index finger in hypoplasia of the thumb. Experience with the method of Buck-Gramcko and retrospective analysis of the clinical outcome in a series of 19 pollicizations

Piza-Katzer Hildegunde · Wenger Andrea · Baur Eva-Maria · Estermann Dunja · Rieger Michael

Received: 15 February 2009 / Accepted: 13 March 2009  
© Society of Hand and Microsurgeons of India 2009

## Abstract

**Background** In congenital malformation of the thumb index finger pollicization is a proven method for constructing a new thumb all over the world.

**Methods** A series of 19 pollicizations in 15 patients is presented. In all cases of index finger pollicization the method of Buck-Gramcko is used and the functional outcome is evaluated after Percival's method. Three special cases are described in detail and the preoperative evaluation with a CT-angiography in cases of complex malformations (case 3) for better planning of the surgical steps is recommended. The importance of parent's information soon after giving birth to a child with thumb hypoplasia is described in detail as the postoperative management.

**Results** In children with bilateral deformities of the hand the surgery can be performed in one session, in only 2 cases a second operation was necessary. The postoperative results were excellent and good (Percival's measurement) and the children are now able to perfectly use their affected hand in their day-to-day activities.

**Conclusion** Buck-Gramcko's method of pollicization in congenital thumb malformation gives excellent results. The preoperative planning and exactly following the four key steps is as important as the postoperative management.

**Keywords** Congenital thumb hypoplasia · Pollicization · Functional result · CT-angiography

Piza-Katzer Hildegunde<sup>1</sup> (✉) · Wenger Andrea<sup>1</sup> · Baur Eva-Maria<sup>1</sup> · Estermann Dunja<sup>1</sup> · Rieger Michael<sup>2</sup>

<sup>1</sup>Department for Plastic and Reconstructive Surgery, Medical University Innsbruck, Austria

<sup>2</sup>Department of Radiology, Medical University Innsbruck, Austria

e-mail: hildegunde.piza@i-med.ac.at

## Introduction

For creation of a well-functioning and nearly normal appearing thumb in congenital thumb hypoplasia or aplasia various methods have been proposed [1–3]. The most commonly performed technique is the transposition of the index finger described by Buck-Gramcko [4, 5], with whom the senior author had the privilege to work and perform surgery under his supervision. In the years 1998 to 2008 the senior-author performed 19 pollicizations in 15 children. Our experiences with the technique and modifications as well as functional outcome are presented. Three special cases of pollicization are presented.

## Classification of congenital hypoplasia of the thumb

Congenital thumb hypoplasia is the most distal type of deficiencies of the radial ray, it can occur uni- or bilaterally, as single malformation or combined with other malformations or as part of a syndrome.

Müller 1937 [6] was the first who tried to classify congenital hypoplasia of the thumb. Blauth 1967 [7] formed a system of 5 types with increasing severity and Buck-Gramcko added a Type IIIC.

We consider this the valid classification of congenital thumb hypoplasia. Triplication of the thumb can be classified as type D according to Wood's subdivision of Wasel's type VII [5].

## Indication for surgery

The type I hypoplastic thumb needs no treatment, type II and IIIA an opponensplasty and type IIIB to V the construction of a new thumb. Pollicisation in type IIIB is

controversially discussed in the literature [8, 9] but we consider it as an indication as five cases of type IIIB hypoplasia in our series show.

### Theoretical concept of pollicization

The method of pollicization of the index finger is based on the reconstruction of traumatically amputated thumbs [10–12]. The transposition of the index finger on a neurovascular pedicle was first described in detail by Blauth 1967 [7]. Buck-Gramcko, who has the greatest experience with malformations of the hands because of the Thalidomide-embryopathy in the late sixties, improved the surgical technique [1, 4, 5].

In creating a new thumb out of the index finger the following points are the fundamentals to the success leading to a functioning thumb: (a) correct skin incision, (b) optimize the position, (c) reduce the length of the bones, (d) stability of the new saddle joint. The operative technique is described in detail in Buck-Gramcko's point of technique and at this point we only want to refer to this article [4, 5].

### Postoperative regimen and therapy

*The thermoplastic-splint can be worn during daytime as a protection as well as a grip support.*

After pollicization we recommend a short anesthesia for removing the sutures 2 weeks postoperative and a fixation of the new thumb in 40–50° palmar abduction. During this anesthesia a thermoplastic splint can be adjusted on the pollicised index-finger to immobilise the CMC and MP joint for another 4–6 weeks (depending on X-ray results). The IP joint can be free so that the child learns to use the tip-to-tip grip to the long finger with its new thumb. If the interdigital grip III/IV is still used by the child during playing a circular elastic Velcro around these two fingers can be helpful to provoke the use of tip-to-tip-grip to the new thumb. After removing the splint the parents are asked to apply a bandage in the first interdigital space during the night for keeping the position of the thumb in palmar abduction.

### Patients and methods

Pollicization was performed on 15 children – 19 hands. Six of them were male, nine female. The age at time of surgery was 9 months to 13 years which is on average 3 years. If we exclude the 13-year-old female patient, since she had surgery performed elsewhere at the age of two, the average age would be 28 months.

In four patients we constructed both thumbs, whereas in two of them we performed simultaneous pollicization,

while in the other two we did it in two sessions. In five out of 11 patients we operated on the right and in 6 on the left hand only. Three cases required preliminary centralisation of the clubhand.

### Types of hypoplasia and additional malformations

The distribution of types of hypoplasia in our series ( $n = 19$ ) is as follows:

- N – 1 Blauth type IIIA
- N – 5 Blauth type IIIB (1 triphalangeal Blauth type IIIB, 1 operated on at 2 years stabilization)
- N – 3 Blauth type III Buck-Gramcko C
- N – 5 Blauth type IV
- N – 4 Blauth type V
- N – 1 thumb triplication Wassel type VII, Wood type D, radial thumb Blauth type III

After informed consent we did a preoperative CT-angiography on all our patients. It can show bones, tendons and blood vessels three-dimensionally. It is a relatively new but invasive technique. However, it can be less invasive if the contrast agent is introduced via a peripheral vein instead of an arterial catheter. The exposition towards X-rays is four times lower than with regular angiography. Examination time and complication rate are smaller as well. The investigation was performed in one day preoperatively under short general anesthesia. The results have been presented on various congresses and will be published in detail elsewhere.

A list of associated anomalies in addition to thumb hypoplasia in our patients is shown in Table 1. In 4 children hypoplasia of the thumb was the only congenital malformation.

### Complications and reoperations

In the postoperative period in one patient a 1 : 1.5 cm necrosis occurred on the back of the hand but healed uneventfully.

In the case of triplicated thumb we had to reoperate about 4 years after the pollicization because a dislocation of the head of the metacarpal bone occurred and a correction with a reposition and stabilization was performed.

In a child with bilateral hypoplasia and a radial club hand on one side we had to shorten the new EPL in a second operation.

### Assessment

Although there are many approaches toward assessing the outcome of pollicization surgery [13–16] we decided to use the method according to Percival because it is simple

and judges function, mobility, sensibility and cosmetic aspects (Table 2).

The examination was carried out by an independent occupational therapist in use of the Biometrics E-LINK Evaluation (Biometrics Ltd., Gwent, UK). The postoperative follow-up lies between 1 and 10 years (on average 4.5).

### Results (Table 3)

The patient with the poor result (11 total points) was diagnosed with Blauth type IV and an additional hypoplastic index finger with instability of the PIP joint and lack of the deep flexor tendon. In the 6-year follow-up he had no pinch-grip. The abduction was smaller than 45° and the appearance was not satisfying.

In two patients with four operated hands the grip-strength could not be measured in the follow-up because they were too young. And three patients with five operated hands could not grasp a tennis ball because their hands were too small which worsens the outcome in Percival's assessment.

Growth of the new thumb was good in all cases. In all patients the sensibility after pollicization was excellent, as no nerves were injured during the operation. When the child is old enough the two-point discrimination can be undertaken to prove the sensibility of the pollicised thumb. With very small children and babies we ask parents whether the child hurts itself without noticing, or uses the thumb spontaneously for using the tip-to-tip-grip and we test the thumbs' sensitivity with soft materials (like a cotton-swab, soft brush, etc.) and observe the child's reaction.

**Table 1.** Incidence of additional malformations in our series ( $n = 11$ ), in 4 children hypoplasia of the thumb was the only deformity

Additional malformations ( $n = 11$ )	
$n = 2$	Brachyphalangia
$n = 1$	Intestinal obstruction, horseshoe kidney
$n = 1$	Mayer Rokitansky Küster syndrome, kidney aplasia, GER
$n = 2$	VACTERL syndrome (rudimentary ears, enterostenosis, vertical scoliosis, congenital hip displacement)
$n = 1$	Holt-Oram syndrome
$n = 1$	VSD, intracerebral haematoma
$n = 1$	Pulmonary stenosis, VSD, duodenal atresia
$n = 1$	Congenital bilateral cataract, duodenal atresia
$n = 1$	Acro-renoocular syndrome
$n = 3$	Additional radial club hand

### Case reports

#### Case 1

Presented was an 11-year-old girl with type IIIB hypoplastic thumb on the right hand.

At the age of two an opponensplasty with transfer of the superficial flexor tendon of the fourth finger performed elsewhere was attempted unsuccessfully. It resulted in a totally instable MP-joint of the thumb (Fig. 1) which made the whole thumb useless. Since she was not able to write with her right hand she was forced to become a sinistral.

We operated on the girl at the age of 13 years and used the method according to Buck-Gramcko [5]. Seven years postoperatively the girl uses her right hand in all activities of daily life, i.e. working as a secretary without restriction in her fine or gross motor skills. Pinch to long till little finger is possible (I/III – 3.2 kg right, 6.7 kg left), gross strength 14 kg right, 33.5 kg left. The radial abduction of the thumb is 60° compared to 80° on the left hand. The two point discrimination in the new thumb is –2 mm. The result of Percival et al assessment was excellent (20 points, Table 2).

#### Case 2

A newborn boy with bilateral malformation of the hand was presented. He was diagnosed with thumb aplasia Blauth type V on the right hand. On the left forearm he had proximal radioulnar synostosis and thumb hypoplasia Blauth type IIIA and synostosis between MC III/IV. We did a pollicization of the index finger on his right hand at the age of 9 months. In the left hand we stabilized the MP joint of the malformed thumb (Fig. 2).

Ten years after the surgery we could take the following measurements. Pinch to middle, ring and little finger is possible (pinch grip I/III – 2.4 kg right), gross strength 6.4 kg right, 3.5 kg left. Radial abduction of the thumb is 65° on the right hand. He uses the right hand as his dominant one. Two point discrimination in the new thumb is 2 mm. The result of Percival et al assessment was excellent (22 points, Table 2).

#### Case 3

This 8-month-old girl had no additional malformation except a radial polydactyly with a triple thumb in the right hand, which was investigated by CT-angiography (Fig. 3). We classified the triplicated thumb as Wassel type VII, Wood type D, the radial thumb was hypoplastic Blauth type IIIB. The second ulnar metacarpal had two epiphyses with two three-phalangeal thumbs. The hand had an ulnar and a radial artery, where the latter sent a

**Table 2.** Functional and cosmetic outcome after index finger pollicization according to Percival et al [15], evaluation of our three presented cases in detail

Functional and cosmetic outcome (Percival et al 1991)		Points	Case 1 (right)	Case 2 (right)	Case 3 (right)
Tip pinch	Strength (< 25%, 25-75%, > 75%)	0-2	1	2	2
	Accuracy (unable, with difficulty, with ease)	0-2	1	2	2
Pulp pinch	Strength (< 75%, > 75%)	0-1	1	1	1
	Accuracy	1	1	1	1
Opposition	To middle	1	1	1	1
	To ring	1	1	1	1
	To little	1	1	1	1
Grasp	Grasp tennis ball	1	1	1	1
	Grasp table-tennis ball	1	1	1	
	Strength (> 75%)	1	1	1	1
Mobility	CMC joint motion	1	1	1	1
	MP joint motion	1	1	1	1
	IP joint motion	1	1	1	1
Sensibility	Normal two-point discrimination, 5-10 mm, > 10 mm	3-1	3	3	3
Cosmetic	Length	1	1	1	1
	Abduction 45-80°	1	1	1	1
	Rotation 90-160°	1	1	1	1
	Appearance	1	1	1	1
Total		22	20	22	22

**Table 3.** Evaluation of the outcome in our series according to Percival's measurement ( $n = 19$  pollicized hands in 15 children)

Outcome measurement ( $n = 19$ )		
Excellent	>20	7
Good	16-19	11
Fair	12-15	1
Poor	<12	0

strong superficial palmar branch to the hand. At the age of 11 months we removed the radial hypoplastic and the ulnar three-phalangeal thumb and pollicised the middle three-phalangeal thumb. This case was reoperated 4 years later because the head of the metacarpal bone was tilted. We corrected the position and fixed the bones with two key wires.

Five years after the first operation tests showed that pinch strength on the right is 1.5 kg and 1.6 kg on the left. Gross strength is 6.9 kg right and 7.4 kg left. Unrestricted use can only be made of the right hand. Two-point discrimination is 3 mm. The result of Percival et al assessment was excellent (22 points, Table 2).

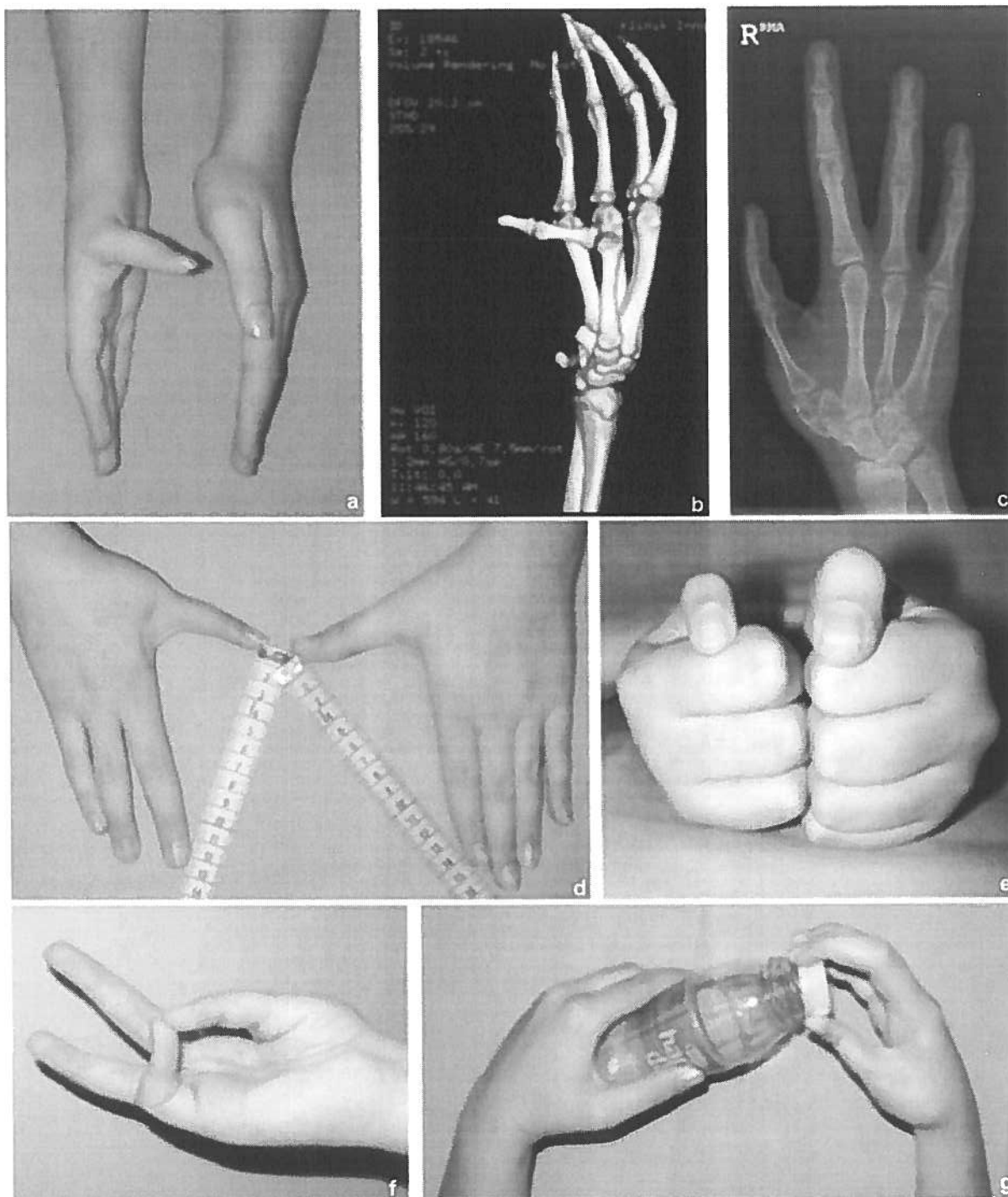
## Discussion

It is not easy to deal with a child's disability so we want to emphasise the importance of parent education and

counseling. The pediatrician needs to be familiar with the fact that there are possibilities to improve the global hand function with an operation and that there are specialists who perform these sophisticated procedures. In order to give appropriate guidance it is crucial that parents be informed of the possible steps to be taken very soon after birth. A hand surgeon with experience in correcting congenital malformation in children can give advice and help decide what to do at which time [17]. This is also to enhance the acceptance of children with congenital malformation in general and therefore it is necessary that there is a team of doctors and therapists that can give those children the best chances and care they deserve.

We always make sure our patients who are to undergo pollicization surgery and their parents get to meet somebody who has had the operation performed. This insures they know about the possible outcomes - positive as well as negative. They need to be informed that additional surgeries might be necessary after pollicization.

Postsurgical therapy is usually not necessary but parents need to be instructed that their encouragement to use the hand is of great importance. Naturally, the child will prefer the hand that was not operated on, especially when it is the dominant hand. But training the new thumb can only be accomplished if the hand is used regularly in everyday life. Children should undergo this surgery in the first year of life so that they can easily train the function



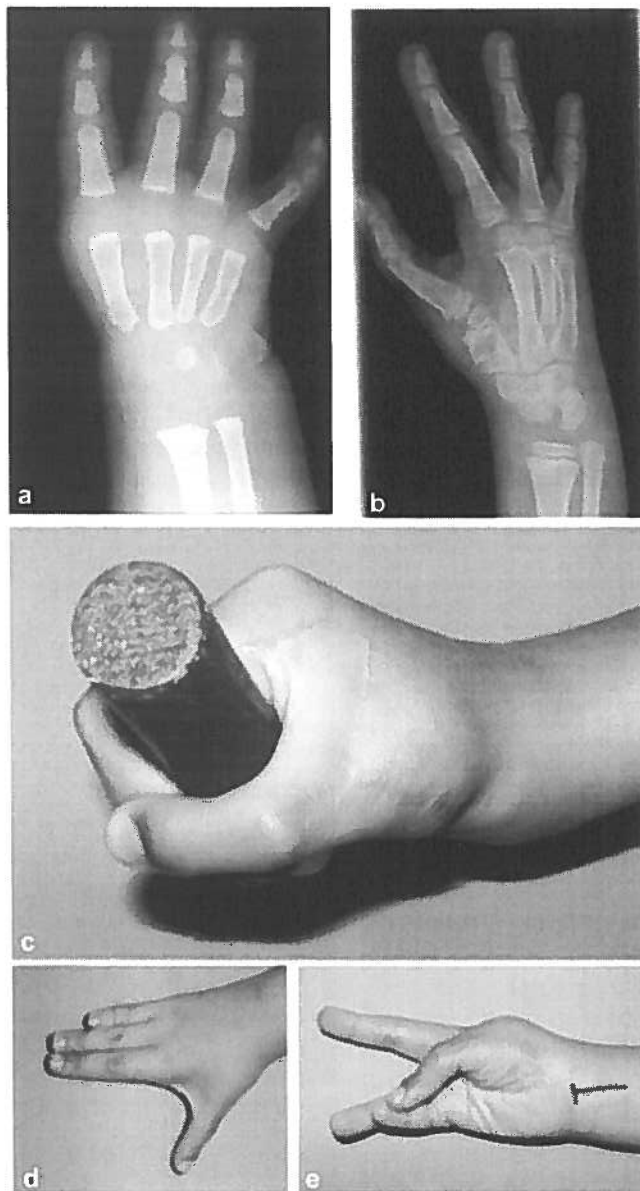
**Fig. 1** a and b, 13 y/o girl, Blauth IIIB, complete unstable MP joint of the thumb after tendon transfer at the age of 2. c, X-ray 7 years after pollicization. d, abduction and extension of both thumbs e, flexion of both thumbs in the IP joint, the difference in the nail and girth is visible. f, very good pinch grip of the new thumb to the tip of the little finger g, seven years after the pollicization the young female has almost normal function on her right hand in activities of daily living

of the new thumb while grasping and playing. This is also important to ensure a normal psycho-motor development.

In the preoperative documentation we found it very useful (aside from X-rays) to perform CT-angiography especially in complex cases of malformations. (see case 3).

We favor pollicization of the index finger over the transfer of a second toe [3, 18] because of the anatomical situation: In index finger pollicization all the present blood vessels, nerves and muscles can be used. If a toe and its metatarsal are transferred it can be difficult to find

equal structures for anastomosis of the vessels, tendons and coaptation of nerves on the malformed extremity. In pollicization of the index finger sensibility remains patent and the young patient learns within 4 weeks to grasp small objects between the new thumb and the other fingers. Therefore, the toe transfer is a markedly inferior alternative to pollicization if fingers are available [19].



**Fig. 2** a, 9-month y/o boy with a thumb hypoplasia Blauth type V and a mesobrachyphalange of the little finger on the right hand. b, X-ray 10 years after the operation, sign of functional adaptation of the new metacarpal in comparison to the proximal phalanx of the middle finger. c, quite normal function of the right thumb in activities of daily living 10 years after pollicization. d, abduction and extension of the right thumb e, tip-to-tip grip to the little finger

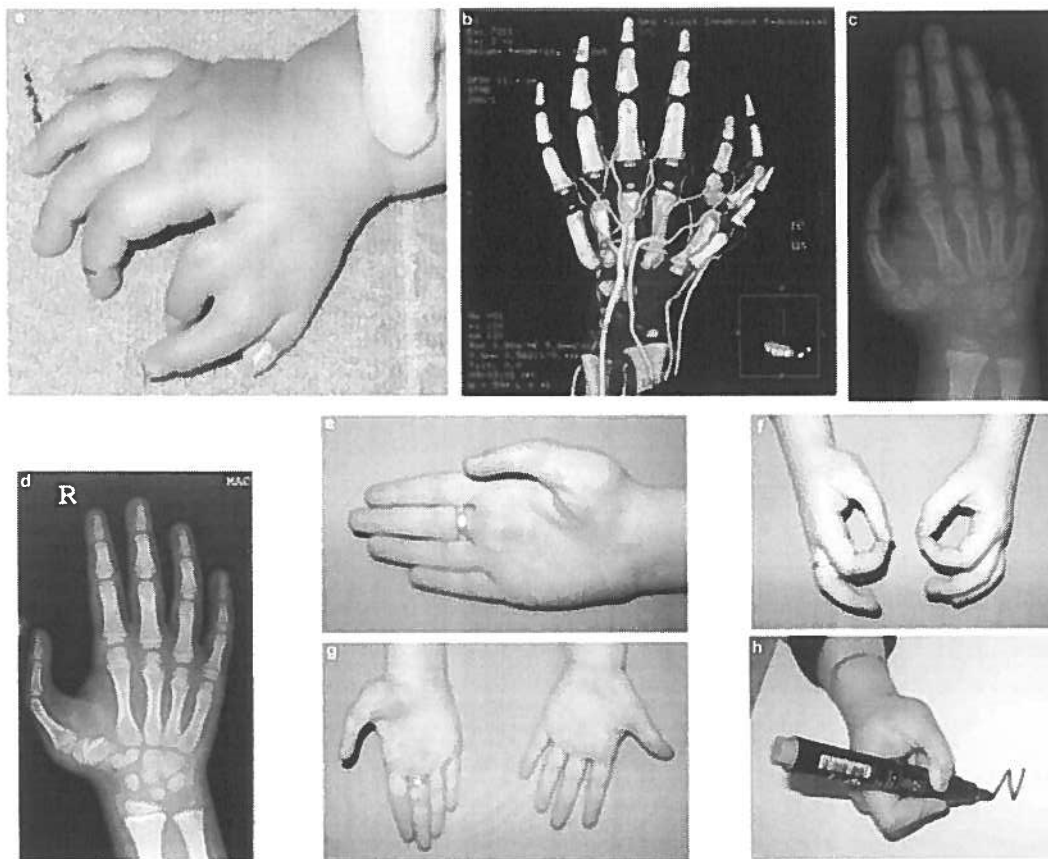
The number of cases of children with hypoplasia of the thumb in our series is very low so we cannot present a statistical significance in any of the parameters we looked at. In the few publications about evaluation of the outcome of pollicization [14–16, 20] it is pointed out that patients with malformations on the ipsilateral hand cannot be compared with those who exclusively have hypoplasia or aplasia of the thumb. Additionally, the question whether the pollicised hand should be compared with hands of age-related groups or the contralateral healthy hand has not been answered yet.

We used the Percival's assessment and know about the difficulties in evaluation because the group of patients is very heterogeneous. First of all, some of the children were too little to grasp a tennis ball which worsens the outcome. Second, in the group of radial club hand and other deformities of the hand the outcome won't be as good as in cases of single hypoplasia of the thumb. Furthermore, these cases can't be compared neither with the contralateral healthy nor with an age-related group. Third, the patients with bilateral affected hands, regardless if they're operated in one or in two sessions, can't be compared with an age-related group.

Regardless of additional deformities we evaluated our patients according to Percival's method: Seven out of 19 operated hands showed an excellent, and 11 a good result. In the only patient with a poor result we have to question whether the indication for pollicization of the hypoplastic index finger was correct (Table 3).

Due to the young age of some of the children it was not possible to test grip measurements or grasp. Only observation of fine motor skills in a playing situation and questioning the child's parents can give additional information. Questionnaire of the parents showed that they all would have the pollicization performed again in their children except in the case with the fair result.

In bilateral hypo- or aplasia of the thumb we have to discuss the advantages and disadvantages of simultaneous pollicization. In our series we have done the surgery simultaneously in two patients. One of them had multiple malformations which required surgery and therefore the parents asked to do the pollicization in one session to keep the time of anesthesia as short as possible. A good pediatric anesthetist prefers to do one longer session which cuts preparation time for monitoring in half. In the other case the parents lived abroad and therefore preferred to have it done in one session. The time it takes to perform two pollicizations in one session decreases with the experience of the surgeon. As we could observe, children are very quick at learning to manipulate with both new thumbs. When there is a one-sided radial deficiency resulting in a radial club hand with a hypoplastic thumb we have to correct the radial club hand first followed by the pollicization of the index finger. In all our patients



**Fig. 3** a, 8-month y/o girl with a triplicated thumb on the right hand, Wassel type VII, Wood type D, hypoplastic radial thumb Blauth type IIIB. b, CT-angiography: the radial artery supports the malformed thumb and the radial side of the index finger c, 4 years after the pollicization the X-ray showed a dislocation of the metacarpal head. d, 5-month after the reposition and stabilization. e, 5 years after the first operation the position and length of the thumb is demonstrated. f, tip-to-tip pinch of the thumb and index finger on both hands. g, in comparison to the left hand restricted abduction of the right thumb is visible. h, the right thumb is used unrestrictedly in activities of daily living

with this type of malformation in our series only good results could have been obtained, as we expected.

We did the pollicization after Buck-Gramcko's point of technique [4, 5] where he states that the basis of the metacarpal can be left depending on the length of the index finger. The modifications made by Foucher [14, 22] aren't proven with long-term follow-up yet, especially regarding abduction of the new thumb. We acknowledge the shorter look of the thumb but we don't recommend the modification of the incision as necessary as the scars at the back of the hand of the children in our series were no problem until now. Comparison of the long term follow-ups of series done after Buck-Gramcko's point of technique and series done after Foucher's modification have to show if the length of the new thumb is adequate for a powerful tip-to-tip pinch to the little finger.

In the literature it is often quoted that the former index finger is remodelling [5]. As far as ours and Goldfarb et al [21] experience goes, the fingernail and the girth of the

new thumb will always remain smaller than a normal developed thumb. In a long term follow-up of 6–10 years in our series we only could notice a remodelling of the transposed proximal phalanx of the index finger in one case (Case 2, Fig. 2b). But what we could observe is remodelling of a new thenar even in hypoplasia Blauth type IV and V, where only two muscles can be used for stabilization of the new thumb.

### Summary and conclusion

We conclude that the pollicization of the index finger in the method of Buck-Gramcko [5] is an adequate technique to create a new thumb in congenital hypo- or aplasia. The results assessed by the method of Percival showed in 18 out of 19 hands (15 patients) excellent and good results. The complication rate was low and until now we only had to reoperate 2 out of 19 hands. In additional clubhand or other deformities of the hand one can never

reach excellent results. In complex cases of hand malformation we recommend to undertake preoperative CT-angiography [23] for better planning the surgical steps.

### Acknowledgements

The paper is based on an invited lecture on the 2nd combined meeting of the Indian Society for Surgery of Hand (32nd annual meeting) and of the British Society for Surgery of Hand in Bangalore, 27–30 November 2008.

### References

- Buck-Gramcko D (1969) Operativer Daumenersatz bei Aplasie und Hypoplasie. *Beilage Z Orthop* 105:417–421
- Foucher G, Medina J, Loréa P, Pivato G, Szabó Z (2004) Pollicization in congenital differences. *Handchir Mikrochir Plast Chir* 36:146–151
- Lister G (1985) Reconstruction of the hypoplastic thumb. *Clin Orthop Relat Res* 195:52–65
- Buck-Gramcko D (1971) Pollicization of the index finger: method and results in aplasia and hypoplasia of the thumb. *J Bone Joint Surg* 53A:1605–1617
- Buck-Gramcko D (1998) Pollicization. congenital malformations of the hand and forearm. Churchill Livingstone
- Müller W (1937) Die angeborenen Fehlbildungen der menschlichen Hand. Thieme Leipzig
- Blauth W (1967) Der hypoplastische Daumen. *Arch Orthop Unfallchir* 62:225–246
- Nishijima N, Matsumoto T, Ymamuro T (1995) Two stage reconstruction for the hypoplastic thumb. *J Hand Surg* 20A:415–419.
- Shibata M, Yoshizu T, Seki T, Goto M, Saito H, Tajima T (1998) Reconstruction of a congenital hypoplastic thumb with use of a free vascularized metatarsophalangeal Joint. *J Bone Joint Surg* 80A:1469–1476
- Gosset J (1949) La Pollicisation de L'index (technique chirurgicale). *J Chir (Paris)* 65:403–411
- Hilgenfeld O (1950) Operativer Daumenersatz und Beseitigung von Greifstörungen bei Fingerverlust. Enke Stuttgart
- Littler JW (1953) The neurovascular pedicle method of digital transposition for reconstruction of the thumb. *Plast Reconstr Surg* 12:303–319
- Aliu O, Netscher DT, Staines KG (2008) A 5-year interval evaluation of function after pollicization for congenital thumb aplasia using multiple outcome measures. *Plast Reconstr Surg* 122:198–205
- Foucher G, Medina J (2005) Principalization of pollicization of the index finger in congenital absence of the thumb. *Tech Hand Up Extrem Surg* 9:96–104
- Percival NJ, Sykes PJ, Chandraprakasam T (1991) A method of assessment of pollicization. *J Hand Surg* 16B:141–143.
- Staines KG, Majzoub R, Thornby J, Netscher DT (2005) Functional outcome for children with thumb aplasia undergoing pollicization. *Plast Reconstr Surg* 116:1314–132
- Hostin R, James MA (2004) Reconstruction of the Hypoplastic Thumb. *Am Soc Surg Hand* 4:275–290
- Foucher G, Medina J, Navarro R, Nagel D (2001) Toe transfer in congenital hand malformations. *J Reconstr Microsurg* 17:1–7
- O'Brian BM, Black JM, Morrison WA, MacLeod AM (1978) Microvascular great toe transfer for congenital absence of the thumb. *Hand* 10:113–124
- Abdel-Ghani H, Amro S (2004) Characteristics of patients with hypoplastic thumb: a prospective study of 51 patients with the results of surgical treatment. *J Pediatr Orthop B* 13:127–138
- Goldfarb CA, Deardorff V, Chia B, Meander A, Manske PR (2007) Objective features and aesthetic outcome of pollicised digits compared with normal thumbs. *J Hand Surg* 32A:1031–1036
- Loréa P, Medina J, Navarro R, Foucher G (2008) Principalisation of pollicization in congenital conditions. Technical modifications for functional and aesthetic improvement. *Chir Main* 27(Suppl 1):540–547
- Klein MB, Karanas YL, Chow LC, Rubin GD, Chang J (2003) Early experience with computed tomographic angiography in microsurgical reconstruction. *Plast Reconstr Surg* 112:498–503